URGANCH DAVLAT TIBBIYOT INSTITUTI
JANUBIY OROLBO‘YI TIBBIYOT JURNALI
2 - TOM, 6 - SON. 2026
14.00.00 - TIBBIYOT FANLARI ISSN: 3093-8740

УДК: 616.37-002.2-091

PANCREAS IN ACUTE FORM OF CHOLEDOCHOLITHIASIS MORPHOLOGICAL CHANGES IN THE GLAND



Rakhimov Izzat Ravshanbekovich – head of the surgical department
“Uzbekistan Railways” Railway Social Services Urgench Settlement Hospital Branch (Tashkent, Uzbekistan). **Email:** izzatbek1232@gmail.com

https://orcid.org/0009-0004-5870-5895

Abstract: Gallstone disease in 10% of the world's population is high in asason women characterized by. The main place in the mechanism of development of gallstone disease constitutional structure of the female body, violation of metabolism, exocrine explained by disorders and disorders of immunopathological processes. Shu indirect or predisposition to the development of gallstone diseases along with factors of birth also occupy a large place. Including obesity low-motile lifestyle, excessive consumption of semi-finished products, smoking, chronic stress and eating processes in the Daily pala burst gastrointestinal tract and it eliminates the smooth functioning of the liver. In very rare factors, abnormalities in the development of the gastrointestinal tract and biliary tract, fetal, abdominal secondary after large reconstructive surgical procedures in the cavity develops after complications. This type of predisposition or secondary total 1.3-5.2% of gallstone disease caused by factors the fact that it turned out to be relevant to the problem.

Key words: gallstones, disease, pancreas, morphological indicators, bile ducts.

OSHQOZON OSTI BEZI XOLEDOKOLITIAZNING O‘TKIR KO‘RINISHIDAGI MORFOLOGIK O‘ZGARISHLARI

Rahimov Izzat Ravshanbekovich – jarrohlik bo'limi mudiri
“O'zbekiston temir yo'llari” temir yo'l ijtimoiy xizmatlari Urganch shaharcha kasalxonasi filiali (Toshkent, O'zbekiston)

Annotatsiya: Dunyo aholisining 10 foizida o't toshi kasalligi ayollarda yuqori darajada uchraydi. O't toshi kasalligining rivojlanish mexanizmida asosiy o'rin ayol tanasining konstitutsiyaviy tuzilishi, metabolizmning buzilishi, ekzokrin bezlarning buzilishi va immunopatologik jarayonlarning buzilishi bilan izohlanadi. O't toshi kasalliklarining rivojlanishiga bilvosita yoki moyillik tug'ma omillar bilan birga katta o'rin tutadi. Jumladan, semizlik, kam harakatlanuvchi turmush tarzi, yarim tayyor mahsulotlarni haddan tashqari iste'mol qilish, chekish, surunkali stress va ovqatlanish jarayonlari oshqozon-ichak traktining kundalik faoliyatini buzadi va jigarning uzluksiz ishlashini buzadi. Juda kam uchraydigan omillarda, oshqozon-ichak trakti va o't yo'llari, homila, qorin bo'shlig'i ikkilamchi rivojlanishidagi anomaliyalar bo'shliqda katta rekonstruktiv jarrohlik muolajalaridan so'ng asoratlardan keyin rivojlanadi. Ushbu turdagi moyillik yoki ikkilamchi o't toshlari kasalligining 1,3-5,2% ni omillar keltirib chiqaradi, bu esa muammoga tegishli bo'lib chiqdi.

Kalit so'zlar: o't toshlari, kasallik, oshqozon osti bezi, morfologik ko'rsatkichlar, o't yo'llari.

URGANCH DAVLAT TIBBIYOT INSTITUTI
JANUBIY OROLBO‘YI TIBBIYOT JURNALI
2 - TOM, 6 - SON. 2026
14.00.00 - TIBBIYOT FANLARI ISSN: 3093-8740

ПОДЖЕЛУДОЧНАЯ ЖЕЛЕЗА ПРИ ОСТРОЙ ФОРМЕ ХОЛЕДОКОЛИТИАЗА: МОРФОЛОГИЧЕСКИЕ ИЗМЕНЕНИЯ В ЖЕЛЕЗЕ

Рахимов Иззат Равшанбекович – заведующий хирургическим отделением
Ургенчское поселение «Узбекские железные дороги» (Ташкент, Узбекистан)

Аннотация: Желчнокаменная болезнь, встречающаяся у 10% населения мира, высока у женщин в позднем возрасте и характеризуется конституциональными особенностями женского организма, нарушениями обмена веществ, экзокринной системы и иммунопатологическими процессами. Значительную роль играют также косвенные факторы или предрасположенность к развитию желчнокаменной болезни, наряду с факторами рождения. Включая ожирение, малоподвижный образ жизни, чрезмерное потребление полуфабрикатов, курение, хронический стресс и нарушения пищевых

привычек в ежедневном приеме пищи, это приводит к разрыву желудочно-кишечного тракта и нарушению нормального функционирования печени. В очень редких случаях, после крупных реконструктивных хирургических вмешательств в полости, развиваются вторичные аномалии развития желудочно-кишечного и желчевыводящих путей, а также патологий брюшной полости. Этот тип предрасположенности или вторичного развития желчнокаменной болезни составляет 1,3-5,2% случаев, обусловленных факторами, которые оказались значимыми для данной проблемы.

Ключевые слова: желчнокаменная болезнь, заболевание, поджелудочная железа, морфологические показатели, желчные протоки.

This coincides with the relevance and necessity of the problem, patients with pancreatic necrosis developed in choledocholithiasis, pancreas in the first 2-4 hours, depending on the duration of the process, and not on age, when detected, the death indicator is 3-8%, when detected in 4-8 hours, death If the mortality rate is 16%, within 8-20 hours, and the mortality rate is 24-31%, Characterized by an increase in mortality in the period of more than 1 day to more than 40%, the risk to the life of patients means high. The essence of the research work the relevance of this problem and in the case of gallstone disease, clogging of stones in the bile ducts as a result of reflux of pancreatic fluid, which occurs due to, morphological aspects of pancreonecrosis that occur and relapses the esophagus and based on the coverage of irreversible aspects, most, advanced and in developing countries, the solution to this problem is only surgery means that it has become associated with.

Purpose of the research: pancreas in acute form of choledocholithiasis study of morphological changes in the gland.

Materials and methods: Khorezm region as an object of research with a total of 121 different degrees of gallstone disease in the rapid surgery department a stomach that has been mirojoyed and has been agitated in surgical practice in pancreonecrosis various etiologies at the center of pathological anatomy of the pancreas and the Republic pancreas taken in autopsy of 28 corpses who died with pancreonecrosis diaper tissue was taken. Paraffin bricks were made from the resulting materials and micronamuna were cut under the standard protocol, morphological changes analysis was. The following verification methods were carried out in the research work: Stomach during autopsy of patients who died of panreonecrosis in morphological changes of the pancreas, the following signs were identified. Including diameter in the adjacent areas of the pancreas and biliary tract Sharp blockage of stones with a diameter of 0.3-0.5 cm, grass in these areas dotted blood clots on the inner surfaces of the roads serous paradalis and erosive on the surface the damaged kilns were found to be. Acute most choledocholithiasis stones clogged in the mucous membrane of the common bile duct during the period of 6-12 hours compression of the surface of the mucous membrane occurs in the form of crushing and acute papillitis can come.

URGANCH DAVLAT TIBBIYOT INSTITUTI
JANUBIY OROLBO‘YI TIBBIYOT JURNALI
2 - TOM, 6 - SON. 2026
14.00.00 - TIBBIYOT FANLARI ISSN: 3093-8740

In most cases, these changes occur when the pancreatic secretion is steamed leads to the fact that it remains. This steamed secret stomach in acute processes acceleration of the processes of autolysis and autophagy in the ossinar glands of the pancreas as a result, it is characterized by the development of various forms of pancreonecrosis. Obstruction of the flow of fire occurs in the grass roads above the pressure of leads to an increase. In this, the walls of the grass canals with expanded grass pigment It diffuses through hepatocytes, into the sinusoidal spaces, and into the blood. Bile acute cholestasis in mechanical barriers on the roads deep of hepatocytes leads to violations, cholestatic intoxication. Long-term mechanical jaundice determines the development of acute disorders of all functions of the liver, which manifested by liver failure.

Results: Long-term obturated lesion dimming leads to increased endotoxemia, dystrophic and degenerative changes in many organs and tissues, life of Morpho-functional changes in all systems providing activity leads to exacerbation. Initially, in acute choledochlitiasis, secretin stasis of the common glandular tract in the stomach taking the secretion from the common gland tract in the head and body of the pancreas also into stasis comes. This, in turn, is central and peripheral in the head and body located in the lumen of the acinus, causing the secretion of the gland to stagnate.

As a result, the secretion accumulated in the spaces of the atsinar gland is classified as dark eosinophilic to be visible, the dynamics of the secretion is out of trace, the gland epithelium continued with the presence of dark eosinophilic inclusions even in their cytoplasm, means that there are necrobiosis and severe dystrophic lesions. Mainly thickening of the texture of the basal membrane on the perimeter of the structures of the ossinar gland, the occurrence of fullness in the vessels on the perimeter, plasmactic staining in the gland confirms the presence of a surface in stromal structures. This, in turn, is a decoration. the sparse fibrous connective tissue around it is also plasmatic bulging and steamed reabsorption of secretions into the stroma and parenchyma leads to swelling of the pancreas comes. This leads to compression and stasis of small-diameter stromal vessels.

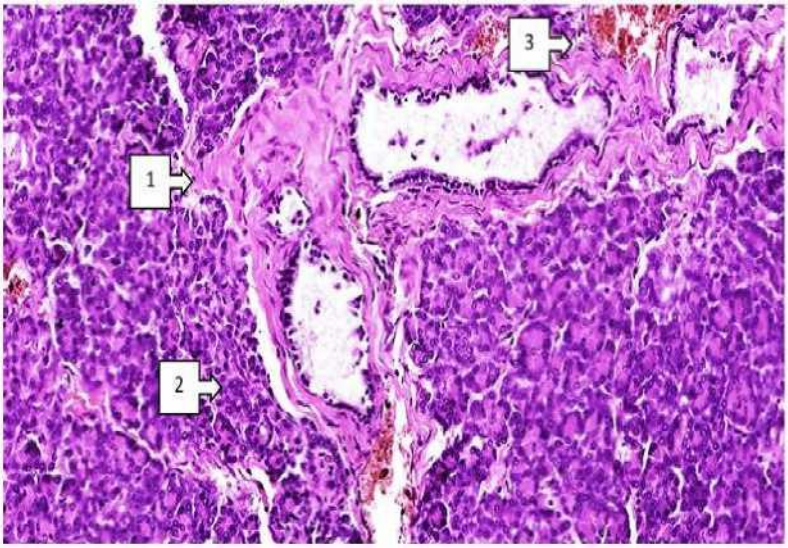

Figure 1. 8-12 hours. Pancreas. Patient is a 49-year-old woman. Suffering from choledocholithiasis. Sclerosis and hyalinosis around the common bile duct foci (1), hyperplasia in the epithelia that make up the gland pathway cavity foci detected (2), venous blood vessel around the common glandular tract dilated and diapedesis blood transfusion foci are detected (3). Paint G.E. 20x10

Clinically morphologically, pancreatic enzymes through the vessels microscopically leading to absorption of dark eosinophin in the vascular cavity leads to an increase in inputs. As a result, the tumor receives the process of regurgitation in the secretion of the pancreas it is determined that the

URGANCH DAVLAT TIBBIYOT INSTITUTI
JANUBIY OROLBO‘YI TIBBIYOT JURNALI
2 - TOM, 6 - SON. 2026
14.00.00 - TIBBIYOT FANLARI ISSN: 3093-8740

occurrence of massive development occurs mainly in 14-18 hours. As a result, 200x had 4-6 necrosis in the visual field in the epithelium of the atsinar gland cells are identified. This is because the first 8-12 sales are standing at 4-6 necrobiosis. implying an increase in relation to epithelia, the process of injury is continuous means that it is going (See Figure 1).

Interstitial in the morphological picture of the pancreas after 6-8 hours expansion of cavities and the occurrence of signs of fullness in vessels of small caliber coming to 10-12 hours, which means that the process of plasmatic staining is intensifying leading to a sharp increase in tumors in the head and body of the pancreas comes. As a result, the pancreas is enlarged and swollen in the general glandular tract caused by irritation of the glandular tract, due to the dimming of secretin the changes that have occurred have been studied.

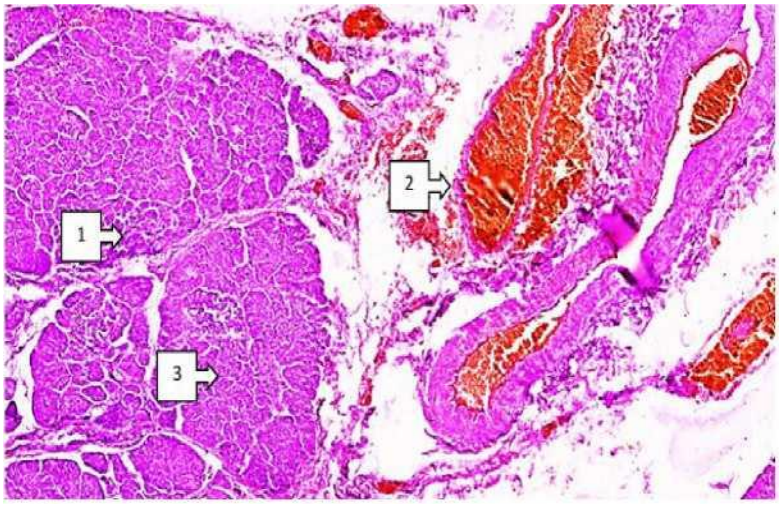

Figure 2. **12-24 hours. Pancreas. Chronic bile duct cough 48 an old woman man. Septa-like attachment on the Gill perimeter a speckled migraine is detected (1). Massive in most venous blood vessels fullness (2), atrophic and hypertrophic on the general background of the ossinar glands foci that have undergone changes are identified (3). Paint G.E. Size 20x10**

Interstitial in the morphological picture of the pancreas after 6-8 hours expansion of cavities and the occurrence of signs of fullness in vessels of small caliber coming to 10-12 hours, which means that the process of plasmatic staining is intensifying leading to a sharp increase in tumors in the head and body of the pancreas comes. As a result, the pancreas is enlarged and swollen in the general glandular tract caused by irritation of the glandular tract, due to the dimming of secretin the changes that have occurred have been studied. The pancreas is macroscopically brown red and hajman enlarged, illvillated with acute autolysis around the common glandular pathways The presence of foci of pancreatic malacia was detected. In our microscopic examination, the gland was found in the lumen of the exocrine gland alveoli. sharp dimming of secretions, dystrophic and necrotic in the epithelium of the glandular tract changes were identified. Including drastic changes mainly the Collector common gland Acute fulminant, destructive changes around small bez structures around the pathways the intermediate tissue encountered and the gland epithelium that underwent necrosis, in these areas diapedesis blood clot foci are detected in enlarged venous vessels. Because bile duct stone disease (choledocholithiasis)is a chronic process atrophic and sclerotic changes in the granular structure of the pancreas it is determined that it has developed.

Conclusion: 1. Choledocholithiasis in its acute form, in the first 2-4 hours, under the stomach dystrophic changes in the atsinar structures of the gland and blunt basophilic in the atsinar spaces proliferation of structures, most dystrophic and necrobiotic in the epithelium of the gland changes were detected, uneven fullness in small-caliber blood vessels.

The next group of choledocholithiasis is in 4-8 hours, in glandular lumps multifocal steatone-crosis, membrane integrity in necrosis-affected glandular epithelia preserved, with foci of necrosis detected in certain areas of the fragments, no drastic changes were detected in the histioarchi-tectonics of most glands. Maida symptoms of fullness in caliber blood vessels and diapedesis blood transfusion foci is determined.

REFERENCES

1. Almas T, Murad MF, Khan MK, Ullah M, Nadeem F, Ehtesham M, Zaidi SMJ. The Spectrum of Gallbladder Histopathology at a Tertiary Hospital in a Developing Country: A Retrospective Study. // Cu- reus. 2020 Aug 9;12(8):e9627.
2. Aripov UA, Aripova NU, Magrupov BA, Ismailov US, Matmurodov SK. Litogennost' zhelchi u bol'nykh zhelchnokamennoĭ bolezn'iu s razlichnymi morfologicheskimi izmeneniiami v tkani pecheni [Lithogenecity of bile in patients with cholelithiasis with different morphologic changes in hepatic tissue] // Khirurgiia (Mosk). 2002;(2):21-2. 18
3. Beltrán MA, Contreras MA, Cruces KS. Pan- creaticobiliary reflux in patients with and without cholelithiasis: is it a normal phenomenon? //World J
4. Surg. 2010 Dec;34(12):2915-21.
5. Brauer BC, Chen YK, Shah RJ. Single-step direct cholangioscopy by freehand intubation using standard endoscopes for diagnosis and therapy ofbil- iary diseases. // AmJ Gastroenterol 2012; 107:10305.
6. Breidert M, Weber M, Wildi S. Unusual Aspect of a Choledocholithiasis. //Gastroenterology. 2020 Nov;159(5):1660-1661.
7. Bragansa J. M., Lee S. H., McCloy R. F. et al. Chronic pancreatitis // Lancet. 2011. Vol. 377. P. 1184-1197.
8. Chen W, Mo JJ, Lin L, Li CQ, Zhang JF. Diagnostic value of magnetic resonance cholangiopancreatography in choledocholithiasis. // World J Gastroenterol. 2015 Mar 21;21(11):3351-60.
9. Dangtakot R, Intuyod K, Ahooja A, Wongwiwatchai J, Hanpanich P, Lulitanond A, Chamgramol Y, Pinlaor S, Pinlaor P. Profiling of Bile Microbiome Identifies District Microbial Population between Choledocholithiasis and Cholangiocarci- noma Patients. Asian Pac J Cancer Prev. 2021 Jan 1;22(1):233-240.
10. Dili A., Bertrand C. Laparoscopic ultrasonography as an alternative to intraoperative cholangiography during laparoscopic cholecystectomy // World Journal of Gastroenterology. 2017. Vol. 23. P. 5438-5450.
11. Draganov PV, Chauhan S, Wagh MS et al. Diagnostic accuracy of conventional and cholangios- copy-guided sampling of indeterminate biliary lesions at the time of ERCP: A prospective, long-term follow-up study. // Gastrointest Endosc.- 2012; 75:347-53.
12. Dray X, Joly F, Reijasse D, Attar A, Alves A, Panis Y, et al. Incidence, risk factors, and complications of cholelithiasis in patients with home parenteral nutrition. J Am Coll Surg 2007;204:13-21.
13. Figueiredo J.C., Haiman C., Porcel J., et al. Sex and ethnic/racial-specific risk factors for gallbladder disease//BMC Gastroenterol, -17.-2017.- p. 153
14. Nortaeva N.A., Nortaev A.B. Morphological changes in teeth against the background of experimental hypothyroidism // Topical issues of modern scientific research.-Dushanbe 2022.-P 168.
15. Nortaeva N.A., NortaevA.B. Morphological changes in the tooth in experimental hypothyroidism // Issues of innovative development of science, education and technology. - Andijan, 2022.-P 273-275

16. Free J, Wang F, Williams N, Gundara JS, Staerkle RF, Hugh TJ, Samra JS. Gallbladder mucosal lesions associated with high biliary amylase irrespective of pancreaticobiliary maljunction. //ANZ J Surg. 2018 Jun;88(6):E517-E521.